

# Laser Face-Lifts: A New Paradigm in Face-Lift Surgery

Patrick McMenemy, M.D.<sup>1</sup>

## ABSTRACT

Laser-assisted liposuction has been successfully applied to remove fat and contract skin in nonfacial areas. This study evaluated the efficacy and safety of this technique in the face. Patients ( $n = 40$ ) requesting improvement and a shorter recovery time received one of four laser face-lift (LFL) procedures. The target area was divided into  $\sim 15$  squares, each around  $5 \times 5$  cm. Each square was treated individually by laser-assisted liposuction to surface temperature end points of  $38^{\circ}\text{C}$  to  $40^{\circ}\text{C}$ . Anatomic areas treated included the submentum, jowls, neck skin, jaw line, cervicomenal angle, oral commissures, and nasolabial grooves. Wavelengths were 1064 nm and 1319/1320 nm. Patients returned to their normal lifestyle within 6 to 7 days after treatment. Patient satisfaction was generally higher than that seen in patients receiving a conventional face-lift. Adverse events were limited to burns in two patients. The LFL is a less invasive treatment with acceptable efficacy, reduced downtime, shorter recovery, and lower cost compared with the traditional face-lift.

**KEYWORDS:** Endolaser, face-lift, laser lipolysis, liposuction

Standard liposuction refers to the removal of localized areas of fat by suction through a cannula. It is one of the most popular cosmetic surgical procedures in the world. The technique, however, can be associated with arm fatigue of the operator, long procedure duration, blood loss, and bruising.<sup>1</sup> To overcome these disadvantages, laser-assisted liposuction (LAL) has been introduced. LAL is the use of a laser fiber (inside or outside a cannula) to treat fat before removal by suctioning.<sup>1</sup> LAL has gained popularity since Apfelberg,<sup>2</sup> using an Nd:YAG laser, reported the results of a multicenter trial of this technique. In this trial, liposuction was performed with a standard cannula, into which a laser fiber was placed. The purpose of the laser beam was to reduce blood loss by destroying adipose cells with light and heat rather than relying on me-

chanical trauma produced by the back-and-forth movements of the cannula. The author concluded that compared with standard liposuction, LAL was less traumatic to the patient and diminished pain, blood loss, swelling, and bruising as well. The author also concluded that the new technique, despite its advantages, offered no clear clinical benefits over standard liposuction.

During the next several years the term "laser lipolysis" came into use. Laser lipolysis may be a one-step procedure, in which a laser fiber is used to treat the fat without suctioning, or a two-step procedure in which the laser is used just prior to suctioning.<sup>1</sup> Research continued as Badin and colleagues,<sup>3</sup> in 2002, reported their use of laser lipolysis to possibly induce skin shrinkage as well as destroy fat cells. They used a

<sup>1</sup>Sciton Inc., and Cynosure, Inc., Sacramento, California.

Address for correspondence and reprint requests: Patrick McMenemy, M.D., 785 University Avenue, Sacramento, CA 95825 (e-mail: drmack@renewyou.com).

New Technologies in Facial Plastic Surgery; Guest Editor, Grant Hamilton, M.D., F.A.C.S.

Facial Plast Surg 2011;27:299-307. Copyright © 2011 by Thieme Medical Publishers, Inc., 333 Seventh Avenue, New York, NY 10001, USA. Tel: +1(212) 584-4662.

DOI: <http://dx.doi.org/10.1055/s-0031-1283049>.

ISSN 0736-6825.

1064-nm Nd:YAG laser to treat flaccid areas of the skin of 245 patients. Laser energy was delivered via a cannula and fiber introduced through a 2- to 3-mm incision. The fiber was outside (rather than inside) the cannula. The procedure was less traumatic than traditional liposuction because the cannula diameter was small (1 mm), and the laser energy rather than mechanical trauma damaged the fat cells. An important finding of this study was that the laser's thermal effects also resulted in skin retraction and collagen remodeling. This showed that the laser could improve skin retraction in small areas such as in the face with minimal swelling and bruising, a clear advantage over liposuction alone.

The year 2006 was an eventful year for laser lipolysis and LAL. A 1064-nm Nd:YAG laser (Cynosure, Westford, MA) was approved by the Food and Drug Administration for the surgical incision, vaporization, excision, ablation, and coagulation of soft tissues.<sup>4</sup> Ichikawa and colleagues<sup>5</sup> presented histological evidence for ablation of subcutaneous fat tissue after irradiation with a 1064-nm Nd:YAG laser beam. Goldman<sup>6</sup> treated the necks and jowls of 82 patients with LAL using a 1064-nm Nd:YAG laser. Histological studies showed ruptured adipocyte membranes as well as coagulation of both collagen and small blood vessels. Cosmetic improvement was significant and the skin of the cervicofacial region had contracted, indicating that the 1064-nm Nd:YAG laser had caused new collagen synthesis. Kim and Geronemus<sup>7</sup> evaluated a high-energy 1064-nm Nd:YAG laser for the laser lipolytic removal of fat from small anatomic areas, including the submentum. Fat reduction averaged 17% in patients 3 months after the procedure and skin contraction was also apparent. The authors suggested that laser lipolysis may be a viable option to a traditional neck-lift.

The year 2006 was also marked by the publication of a prospective, randomized, double-blinded, controlled trial comparing LAL and suction-assisted liposuction.<sup>8</sup> The authors concluded that LAL offered no major clinical improvements over suction-assisted liposuction. This study was launched to counter advertising claims of unproven benefits of laser liposuction over traditional liposuction.

The popularity of laser lipolysis, however, continued to increase as additional laser manufacturers entered the market and word-of-mouth patient satisfaction spread.<sup>4</sup> In the meantime, Liu and colleagues<sup>9</sup> showed that mouse skin irradiated with a 1064-nm Q-switched laser resulted in increased synthesis of collagen type III compared with irradiation with long-pulsed 1320-nm irradiation and that this difference could be attributed to photomechanical effects, whereas the 1320-nm laser energy resulted in a greater increase in collagen type I due to photothermal effects on the irradiated tissue. These results showed that

1064- and 1320-nm wavelengths could potentially augment the collagen synthesis achieved by either wavelength alone.

Laser lipolysis was further characterized by studies published in 2009. After the findings of Liu and colleagues were published, DiBernardo and colleagues,<sup>10</sup> in their evaluation of the thermal effects of laser energy on abdominal skin, reported that the heat produced by internal laser-tissue interaction with 1064- and 1320-nm wavelengths resulted in lipolysis at the fatty layer and skin tightening at the subdermal layer. The authors also described their grid technique in which 2 × 2-cm squares were drawn on the target area. Each square was treated with the SmartLipo (Cynosure, Inc., Westford, MA) at 1064, 1320, and 1064/1320 nm. Treated tissue was examined histologically for thermal injury. Temperatures at the skin surface and at depths of 5 and 7 mm were recorded. Previous studies<sup>11-15</sup> had shown that skin surface temperatures of ~40°C were associated with dermal temperatures between 60°C and 70°C, which resulted in acute collagen contraction and subsequent collagen remodeling with skin texture improvement in the following months.<sup>10</sup> DiBernardo and colleagues then showed that superficial treatment at surface temps greater than 47°C caused epidermal and dermal injury and surface temperatures of 58°C resulted in blisters. The authors concluded that during laser lipolysis, skin temperatures associated with superficial heating at depths within 5 mm should not exceed 42°C.

In another report,<sup>16</sup> DiBernardo and colleagues showed that this same dual-wavelength combination resulted in a 26% improvement in skin elasticity as well as a 17% reduction in skin area. These findings meant that their treatment protocol could both shrink and tighten skin. Sasaki and Tevez<sup>17</sup> subsequently reported the results of their 75-patient study with updated treatment settings, combinations of 1064- and 1320-nm wavelengths, end point temperatures, histological data, outcomes, morbidities, and recoveries. Sasaki and Tevez achieved tissue tightening in the face, neck, arms, abdomen, and thigh with a low incidence of swelling and bruising.

In 2009, Sun and colleagues<sup>18</sup> reported their use of laser lipolysis to treat localized fat in 35 Asian patients. The authors presented clinical and histological evidence to support their conclusion that lipolysis with the Nd:YAG laser is more effective than conventional liposuction for the treatment of localized adiposis. This was the first report to evaluate in detail the use of laser lipolysis in the face, chin, neck, and arms in Asian patients.

The present report describes in detail the author's experience in the use of laser lipolysis with a grid technique<sup>10</sup> in combination with specific face-lift

**Table 1 LFL Procedural Options**

LFL Number (No. of Patients)	Incisions	Notes
1 ( <i>n</i> = 24)	4 small incisions (2 submental/2 postauricular)	Face and neck grids (subcutaneous only)
2; with/without open submentoplasty ( <i>n</i> = 10)	Submental incision only Submental skin elevation to hyoid Full central midline Platysma address	4–5 cm elevation to clavicle May involve excision of dart/crescent/both
3; mini-face-lift with or without limited submentoplasty ( <i>n</i> = 1)	Very limited preauricular elevation SMAS strip Open limited submentum	Skin elevation (2.5 cm) from root of zygoma to mandibular angle Strip (1 cm, zygoma to mandibular angle)
4; full face-lift ( <i>n</i> = 5)	Open submentum/pre- and postauricular elevation/address of SMAS, laser used to heat skin in the nasolabial/oral commissure/jowl area	—

LFL, laser face-lift; SMAS, superficial muscular aponeurotic system.

procedures in patients seeking improvement with shorter recovery times. It is an anecdotal, exploratory case series. Unlike Sun and colleagues, the author's goal was to achieve skin contraction and tightening rather than fat removal in the face and neck. Further research, clinical application, and analysis are necessary.

## METHODS

### Patients

In this retrospective study, patients (*n* = 40) requesting improvement and a short recovery time received an LFL in an Institute for Medical Quality-accredited office surgery suite between May 2008 and May 2010. Anatomic areas treated included the submentum, jowls, neck skin, jaw line, cervicomenal angle, oral commissures, and nasolabial grooves. Follow-up time was up to 22 months. All patients were healthy, willing to undergo facial surgery, and American Society of Anesthesiologists class 1 or 2. All provided signed informed consent to the procedure after consultation and preoperative counseling. Patients with no facial fat, poor skin contractility or elasticity, or no interest were excluded. Age did not affect eligibility. All procedures were performed by the author.

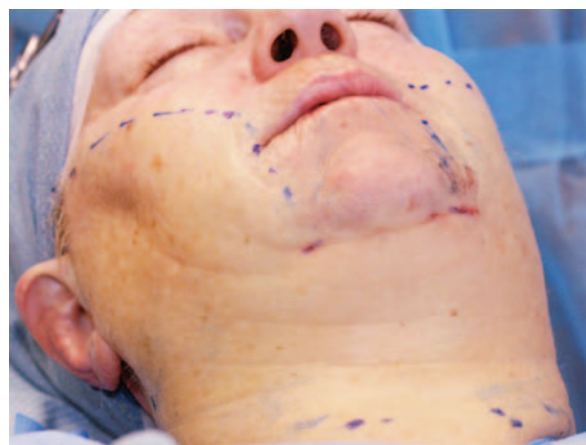Patients underwent one of four procedures (Table 1). This report focuses on LFL 1 (*n* = 24) and LFL 2 (*n* = 10). Five LFL 1 and five LFL 2 patients had previous face-lifts. Among the remaining six patients, one received a mini-face-lift (LFL 3). Five patients who had never undergone face-lift surgery received a complete "standard" face-lift, which included subcutaneous use of the laser in the perioral area to improve the nasolabial grooves, jowls, oral commissures, and lateral upper and lower lips (LFL 4).

### Pretreatment

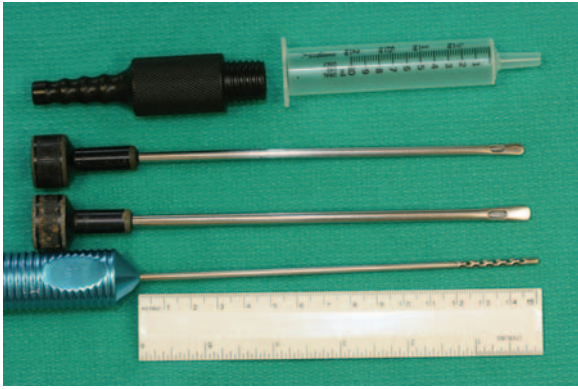
Thirty of the 34 patients who underwent either LFL 1 or LFL 2 received oral diazepam (20 mg) and diphenhydramine (50 mg) 20 minutes before treatment. Four patients also underwent a pretrichial brow-lift, blepharoplasty, or both, and were also given intravenous medication (midazolam [5 mg] and meperidine [100 mg] in 500-mL normal saline drip). A nonflammable antiseptic (pHisoHex/hexachlorophene) was applied to the target area to avoid blue-flame fires during laser surgery. A Sharpie green marker was used to divide the target area into ~15 squares approximating 5 × 5 cm each, depending on the size and configuration of the target area. Green ink persisted longer than blue ink and was easier to remove after the procedure.

### Surgical Technique

Patients undergoing LFL 1 or LFL 2 required 200 to 300 mL of tumescent face-lift solution infused in the

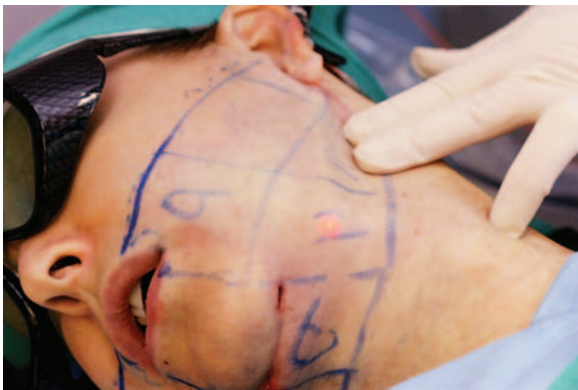

**Figure 1** The neck, submentum, and lower face of a patient in whom the tumescent anesthetic solution has been infused.

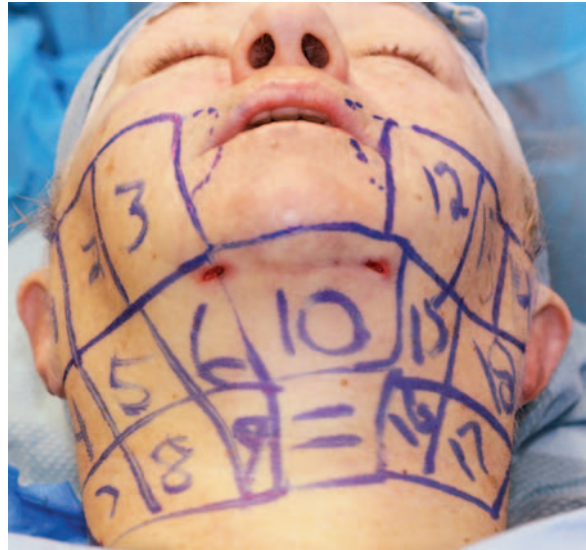

**Figure 2** Instruments used in endolaser face-lifts 1 and 2. From top to bottom are a syringe adaptor, 4-mm spatula, 6-mm spatula, and 2.75-mm Blugerman rasp.

neck and lower two-thirds of the face. A 22-gauge, 3.5-inch spinal needle was used for the infusion. The infusion volume was selected on the basis of the degree of tumescence, anesthesia, and its anticipated effect on the temperature of the tissue during laser treatment. (It was thought in early procedures that lower volumes would have a lesser cooling effect.) Figure 1 shows a patient immediately after infusion. The face-lift solution consisted of lidocaine (750 mg, 0.15%), epinephrine (2.0 mg, 1:250,000), and sodium bicarbonate (7 mEq) in 500 mL normal saline. For incisions, lidocaine (1% with 1:100,000 epinephrine) was used. Tunnels for passage of the laser cannula were created with a spatula cannula (4 mm, 6 mm, or both) without suctioning and a Blugerman rasp (2.75 mm) to further break down septations and subcutaneous attachments. Instruments used during the procedure are shown in Fig. 2 and the cannula and laser fiber inside the neck in Fig. 3. If required, a minimal quantity of fat was aspirated for sculpting in the immediate submental and anterior cervical triangle areas. It was occasionally necessary to use the Blugerman rasp a second time to ensure place-



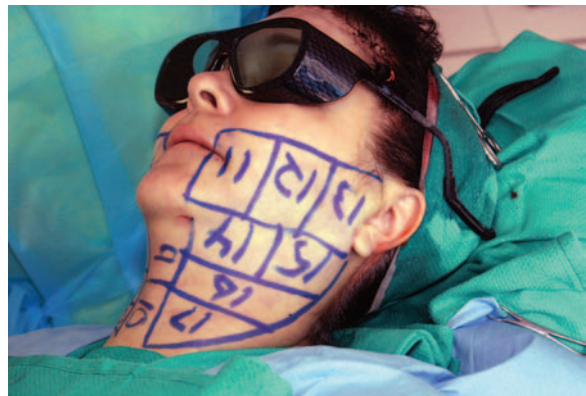**Figure 3** The cannula and laser fiber inside the neck during treatment of a 53-year-old female patient.



**Figure 4** Grid squares (17, ~5 × 5 cm) drawn on the neck, submentum, and lower face of the 55-year-old woman after infusion of the tumescent anesthetic solution. Each square was treated individually.

ment of the 300-, 600-, or 1000- $\mu$ m laser fiber into the lower two-thirds of the face and anterior cervical triangles. It was crucial that the tunnels permit uniform trauma and delivery of laser energy into each grid (Figs. 4, 5) as reflected in surface temperatures and that the surgeon's tactile sense be maintained during the procedure.

Each square was treated with the Joule (Sciton Inc., Palo Alto, CA) or the SmartLipo, using 1064/1319 nm or 1064/1320 nm Nd:YAG laser energy, respectively, delivered by an optical fiber (300, 600, or 1000  $\mu$ m diameter) enclosed in a stainless steel liposuction cannula and extending 2 to 3 mm beyond the distal end. Fifty percent of each wavelength was used with laser power settings the same for each wavelength (e.g., 6 W



**Figure 5** Grid squares on the left neck and lower face of a 54-year-old woman just before laser treatment of the grids. Each square was treated individually.

for 1064 nm and 6 W for 1319 nm, or 5 W and 5 W). Each square received an average of 693 J to achieve an end-point skin temperature of 38°C to 40°C in each square as reported<sup>16,17</sup> to achieve skin tightening. Surface skin temperature was monitored with a handheld infrared thermometer (MiniTemp MT6, Raytek Corp., Santa Cruz, CA). The internal tissue temperature, optimally at 45°C to 47°C to avoid epidermolysis,<sup>16</sup> has more recently been monitored with a TempAssure (Sciton Inc.) or Thermaguide (Cynosure) internal sensor. An He:Ne diode laser beam helped to visualize and guide subcutaneous movements of the cannula during treatment. When treatment was completed, the submental incisions were closed with sutures (5–0 nylon) and the postauricular incisions were left open for drainage. The LFL 2 submental incision was closed with a 5–0 nylon continuous suture.

The volume of blood lost in either LFL 1 or LFL 2 was not significant, averaging 8 mL (range 5 to 15 mL). Fat volume loss averaged only 6 mL (range 0 to 20 mL), although some was probably lost due to mechanical or thermal trauma and not recorded as output.

### Posttreatment

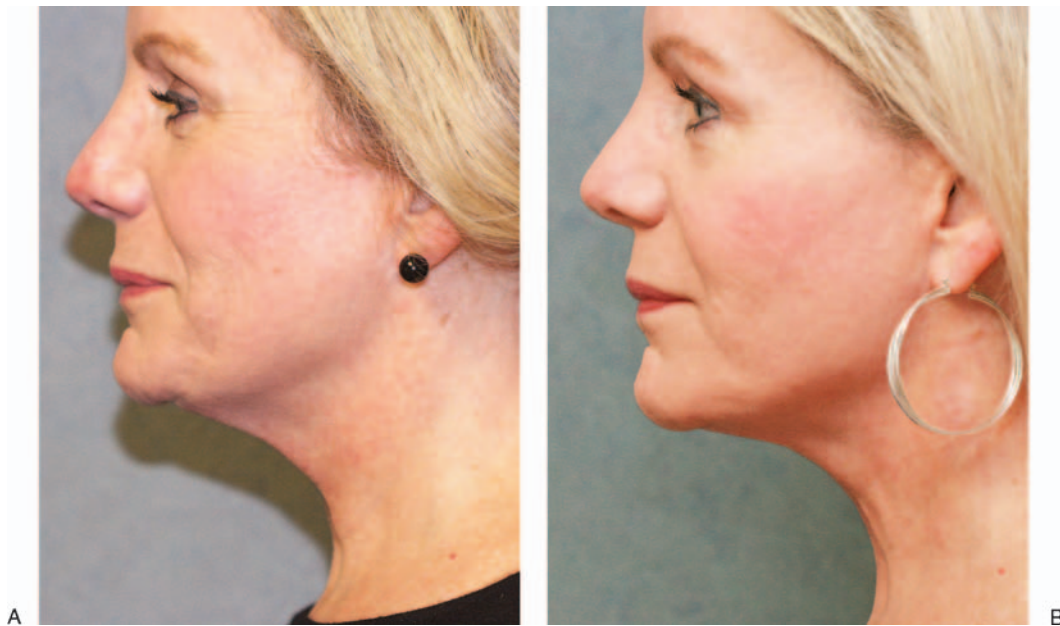Patients wore a face-lift support dressing for 1 day and then an Ace support wrap dressing for 3 to 4 days.

### RESULTS

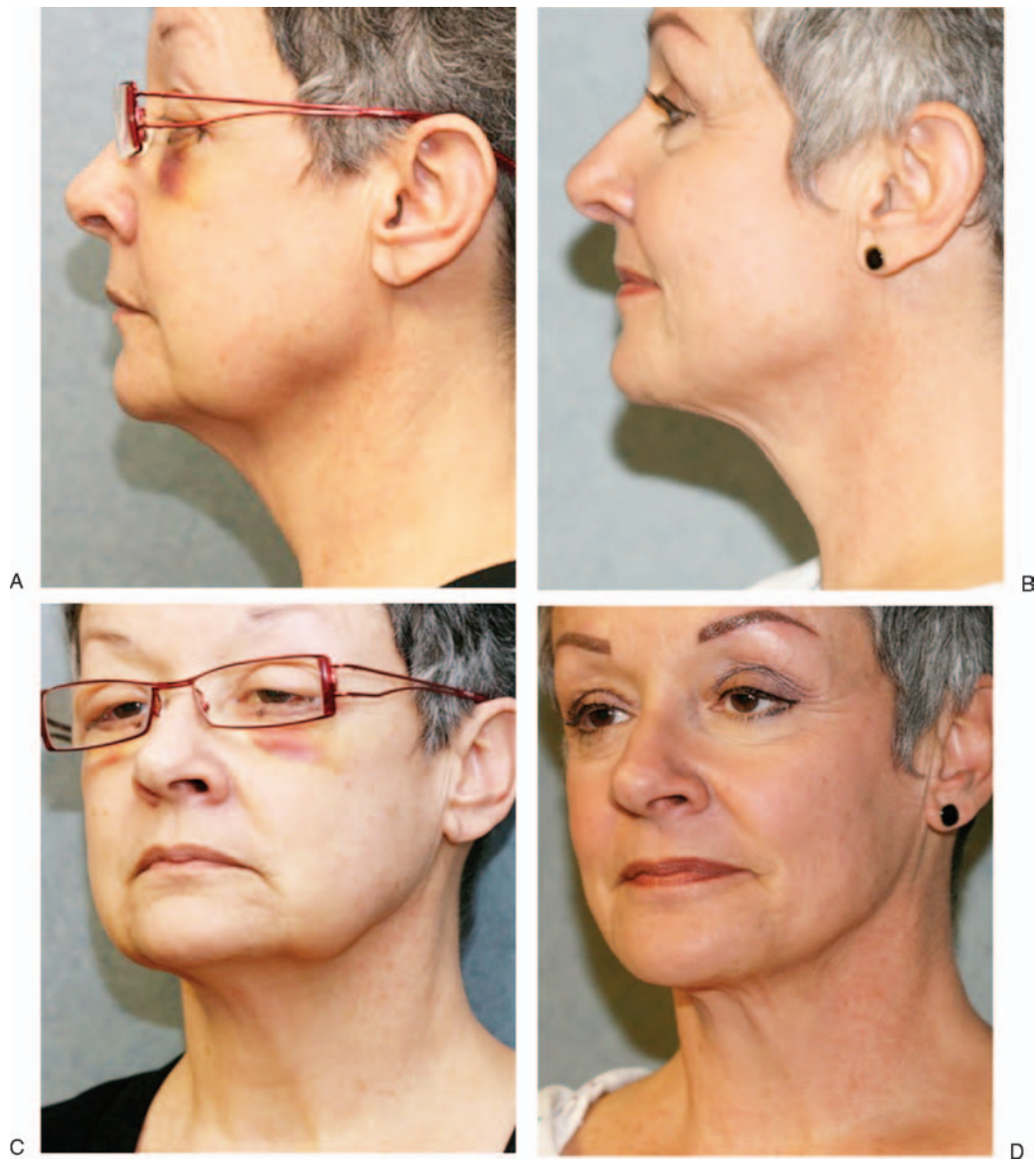Patients tolerated their procedures well. All LFL 1 and LFL 2 patients returned to social events within 6 days and to their jobs within 7 days unless additional procedures were performed with the LFLs. Some returned to work in 3 to 4 days and a few returned the next day. Conventional face-lifts in the author's practice required 10 to 12 days downtime. As for LFL 3 and LFL 4, the number of procedures performed so far is too small to permit conclusions regarding downtime. Clinical examples are shown in Figs. 6 to 8.

At each follow-up visit, patients rated their pain, swelling, bruising, nausea, energy level, and satisfaction. Although numerical data are not available and the number of patients is small, these patients appear to have been more satisfied than those undergoing nonlaser face-lifts in my practice. (This may be a reflection of selection phenomena.) One LFL 1 patient had a "Standard" face-lift 1 year later due to suboptimal improvement in the immediate submentum.

Adverse events were limited to burns in two patients. In one thin-skinned, 78-year-old woman undergoing a revision face-lift (LFL 1), a single burn was noticed in the preauricular area late in the procedure. The heat from the laser appeared to have gone deep over the mandibular angle and came back superficially to cause the burn. The second burn (Fig. 9) occurred in a



**Figure 6** This 57-year-old female (who had previously received a primary face-lift) underwent laser face-lift 2 (LFL 2) with 250 mL tumescent fluid (0.15% lidocaine with 1:250,000 epinephrine) and 9 mL of 1% lidocaine with 1:100,000 epinephrine. The left and right photographs were obtained before and 2 months after surgery, respectively. Internal laser energy of 1064 and 1320 nm (50:50) was delivered at 5 W for each wavelength, and skin temperature was maintained between 38°C and 40°C. Aspirate contained no fat and estimated blood loss was  $\leq$  5 mL. The patient's postoperative results at 2 months show improvement in the left platysmal band (crescent), lower jowl, and jaw line. Fullness over the masseter muscle is reduced and nasolabial grooves are less prominent. The patient returned to her job 3 days after surgery and to a social event 4 days after surgery.



**Figure 7** Three days after lower blepharoplasties, this 57-year-old female underwent laser face-lift 1 (LFL 1) with 350 mL tumescent fluid (0.15% lidocaine with 1:250,000 epinephrine) and 10 mL of 1% lidocaine with 1:100,000 epinephrine. The left and right photographs (lateral and oblique views) were obtained before and 9 months after surgery, respectively. Internal laser energy of 1064 and 1320 nm (50:50) was delivered at 5 W for each wavelength, and skin temperature was maintained between 38°C and 40°C. Aspirate included 20 mL of fat and estimated blood loss was  $\leq 10$  mL. The patient's postoperative results at 9 months show improvement and skin tightening in the jowls and reduced submental fullness. The patient attended a class 3 days after surgery and a social event on day 4.

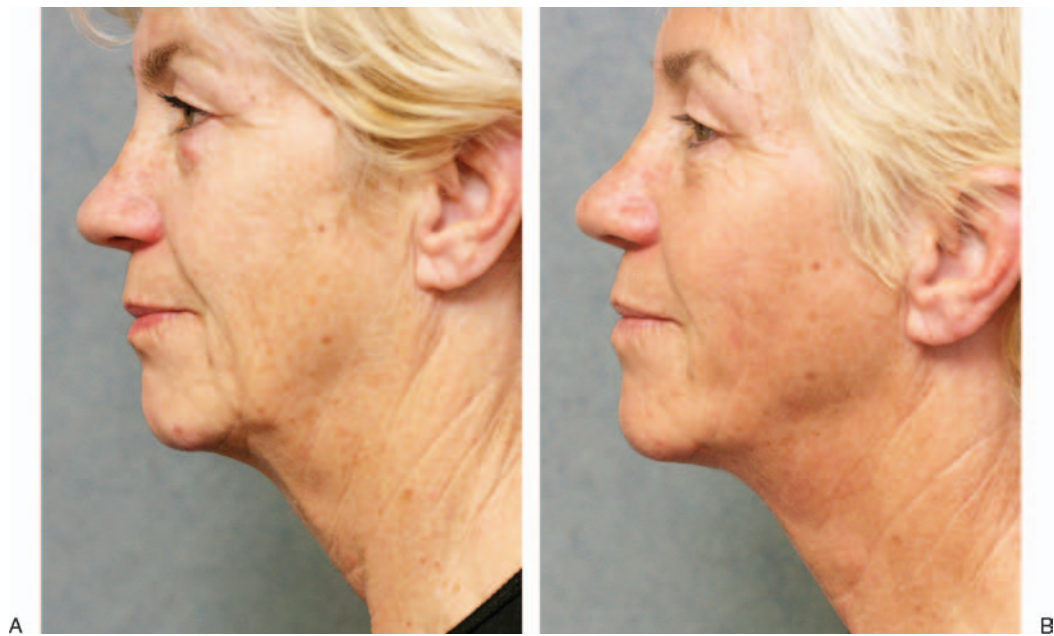63-year old patient during a revision face-lift. The patient had a scar near the corner of her mouth, which flashed immediately when in contact with the laser fiber. The affected area was promptly cooled with ice, but the potential for a rapid increase in temperature was immediately apparent.

There were no injuries to the facial nerve. Sensation returned more quickly to the face and neck (1 to 2 weeks) than normally observed in flap elevation face-lifts. Edema was sometimes greater on the first day after surgery than in a "standard" face-lift," but it cleared more

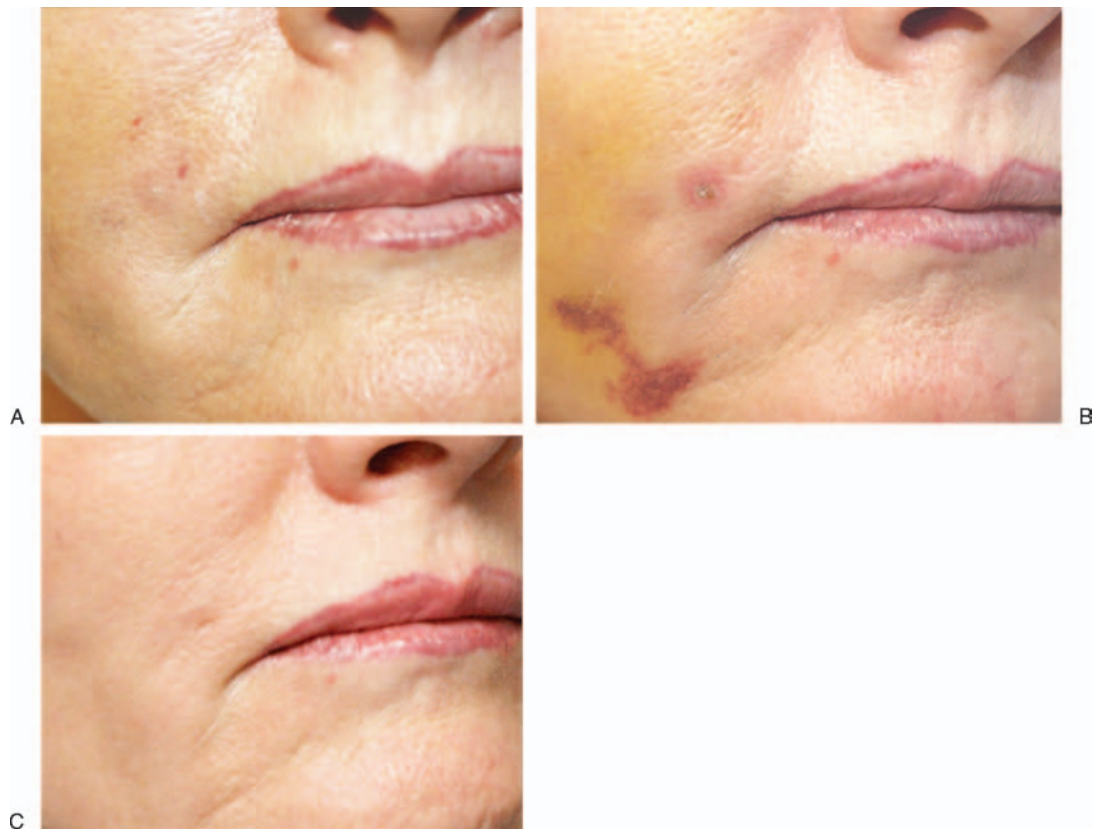
quickly. At times, the skin of the neck and face was hyperemic. Cannula energy delivery at depths of 5 mm produced less bruising than seen with normal face-lifts. Heat and light energy appeared to create a slightly different wound than flap elevation face-lifts.

## DISCUSSION

Although the original goal of laser lipolysis was to remove fat deposits, investigators have found that contraction of the skin envelope was achievable as well. This finding was



**Figure 8** This 55-year-old sun-damaged female underwent laser face-lift 1 (LFL 1) with 300 mL tumescent fluid (0.15% lidocaine with 1:250,000 epinephrine) and 10 mL of 1% lidocaine with 1:100,000 epinephrine. The left and right photographs were obtained before and 3 months after surgery, respectively. Internal laser energy of 1064 and 1320 nm (50:50) was delivered at 5 W for each wavelength, and skin temperature was maintained between 38°C and 40°C. Aspirate contained no fat and estimated blood loss was  $\leq 5$  mL. The patient's postoperative results at 3 months show improvement in laxity in the neck and lower front part of the cheek. The patient returned to her job 3 days after surgery.



**Figure 9** A 63-year-old patient who experienced a burn near the corner of her mouth. The affected area is shown 1 day (A), 6 days (B), and 60 days (C) after a revision face-lift (LFL 1).

important because for aging patients in whom loss of facial fat is common, skin contraction is more important than fat removal. The results of the present study show that procedures proven to achieve skin contraction in nonfacial areas<sup>10,16,17</sup> can provide similar benefits in facial areas such as the submentum, mandibular border, jowl fat pad, and nasolabial grooves. Less dramatic results may be expected in elderly patients with minimal skin elasticity, severe photodamage, or both. These findings are consistent with the current trend in laser lipolysis toward skin contraction of the envelope more than sculpting and obliterating fat cells, the majority of which will be removed by the body (without suctioning) or with suctioning after laser treatment.<sup>10,16,17</sup>

In experienced hands, outcomes from traditional face-lifting procedures depend primarily on age, anatomic shape, skin type, skin texture, photodamage, and healing ability. However, even in the hands of the most skilled surgeon, these facial procedures have limitations in all planes of dissection for the jowls, nasolabial grooves, and oral commissures. For example, a traditional face-lift improves the neck skin, the cervicomenal angle, the lower third of the jowl, and the jaw line, but does not improve the nasolabial groove or oral commissure. Surgical attempts to smooth out these creases include direct excision, dermal grafting, curettage, dermal/fat grafting, and special suturing. All have yielded suboptimal results, especially when patients resume their mimetic function.

The current economy and the willingness of patients to accept lesser improvement in exchange for reduced invasiveness, recovery time, and cost were crucial factors in the author's decision to apply laser lipolysis to face-lifts. Patients are attracted to the author's procedure because compared with a traditional face-lift, the procedure is new, includes a laser, requires smaller incisions, tightens skin, has less downtime, and results in less bruising and bleeding. The procedure is also less expensive and requires no general anesthesia. This preference for a "freshening procedure" over a "major overhaul" represents a major shift in cosmetic surgery that became apparent in the author's practice during 2008. This trend was the rationale for combining laser lipolysis and facial plastic surgery. Another trend is an increased need for the cosmetic surgeon to focus on the specific needs and desires of the patient rather than to strive for an equal balance between (1) which procedures the patients want and (2) the procedures the surgeon is willing to perform. In the author's practice, this balance has shifted greatly to the patient's side, due again to the current tight economy.

Patient satisfaction with results is another key factor. In the author's practice, patients who undergo a laser face-lift procedure are generally more satisfied than patients who receive a traditional face-lift. This is attributable to careful choice of patients, encouraging realistic

expectations, and obtaining informed consent. Patients are especially elated when they see greater improvement than expected and experience a short, easy recovery.

A disadvantage of including laser lipolysis in face-lift procedures is the cost of the laser. The argument against this point of view is that cosmetic surgeons who choose not to offer a less invasive procedure with an easy recovery may not even be consulted by patients who cannot afford the down time or the higher cost of a traditional face-lift.

The use of laser energy to support the time-honored face-lift is new to most facial plastic and cosmetic surgeons. It is therefore appropriate to discuss the factors that influence outcomes with laser lipolysis. In a nonlaser face-lift, outcome depends on repositioning, redraping of tissues, and addressing musculature, fat, and skin. Skin laxity and movement of tissue in the mimetic face must also be considered. With a laser face-lift, outcome depends on tissue heating as well as mechanical trauma. DiBernardo and colleagues<sup>10</sup> have evaluated tissue heating for superficial and deep laser lipolysis and correlated surface and internal temperature changes with both clinical and histological effects. These authors treated abdominal skin with 1064-nm, 1320-nm, and both wavelengths in rapid sequence at 3- to 5-mm (superficial, subdermal) and 20-mm (deep fatty layer) depths. Laser doses ranged from 8.3 to 333 J/cm<sup>2</sup>. They found that superficial treatment at skin surface temperatures of 47°C (50°C to 55°C at 5 mm depth) injured both the epidermis and dermis, and that skin surface temperatures exceeding 58°C caused blisters. Below 47°C, however, epidermal injury was not observed and many samples showed focal collagen change and a dermal inflammatory response. DiBernardo and colleagues suggested that these observations may be linked to skin tightening as the treated areas healed. They concluded that skin surface temperature during laser lipolysis should not exceed 42°C to avoid tissue injury. As for deep treatments, skin surface temperature did not increase significantly during treatment. Histological studies revealed focal hemorrhage, vascular congestion, edema, and, in dermal ligaments, swelling and hyalinization of collagen fibers. Temperature monitoring at various depths indicated that there were minimal increases in temperature for laser doses up to 133 J/cm<sup>2</sup> and that higher doses, although causing increases in temperature, did not cause histological tissue injury.<sup>10</sup>

In the present study, the author's ultimate goal was to develop a procedure in which outcomes are determined by the uniformity of both mechanical trauma and heat application. In that spirit, the author has applied the findings of DiBernardo and colleagues on abdominal skin to the face and neck. The author has found that skin surface temperatures between 38°C and 40°C result in positive outcomes and minimal adverse effects as shown in Figs. 6 through 8. Another finding is

that patterns of heating and energy absorption during the procedure depend on the target tissue. For example, over bone, such as in the jaw line where subcutaneous tissue is sparse, the temperature of the target area reached 38°C to 40°C during treatment. As the laser was moved to another area, the previously treated area was immediately cooled to ~35°C to prevent a temperature increase. When the ice was removed a few seconds later, the area rapidly felt warmer, indicating a rapid return of the temperature to 39°C. Laser energy (as heat) appeared to have moved downward toward the jaw bone and then returned quickly to the skin surface. This phenomenon may explain the burns in two patients. In scar tissue, the skin surface temperature increased rapidly, reflecting this tissue's intolerance to heat. Thin tissue, specifically in the preauricular area, was also sensitive to heat. In neck creases, excessive heating could disrupt normal vascular supply, causing acute venous congestion, a potential pitfall not observed with the normal flap elevation techniques.

Another potential issue is wavelength. The author's opinion is the wavelength does not matter. This agrees with Mordon et al<sup>19</sup> who wrote that delivery of energy to the tissues causes a heat-dependent response that does not appear to be related to the wavelength or continuous-wave versus pulsed-wave energy.

The author continues to treat patients and modify the procedure as experience and patient feedback dictate. Additional studies are needed to further optimize the treatment parameters to achieve maximum efficacy and safety.

## CONCLUSION

The laser face-lift as described in the present study offers patients a less invasive treatment with acceptable efficacy, reduced downtime, shorter recovery, and lower cost compared with the traditional face-lift.

## REFERENCES

- Zelickson BD, Dressel TD. Discussion of laser-assisted liposuction. *Lasers Surg Med* 2009;41:709–713
- Apfelberg DB. Results of multicenter study of laser-assisted liposuction. *Clin Plast Surg* 1996;23:713–719
- Badin AZ, Moraes LM, Gondek L, Chiaratti MG, Canta L. Laser lipolysis: flaccidity under control. *Aesthetic Plast Surg* 2002;26:335–339
- Lack E. A new gold standard. *Advance for Healthy Aging for Physicians*. March–April 2010;5:20–24
- Ichikawa K, Tanino R, Wakaki M. Histologic and photonic evaluation of a pulsed Nd: YAG laser for ablation of subcutaneous adipose tissue. *Tokai J Exp Clin Med* 2006; 31:136–140
- Goldman A. Submental Nd: Yag laser-assisted liposuction. *Lasers Surg Med* 2006;38:181–184
- Kim KH, Geronemus RG. Laser lipolysis using a novel 1,064 nm Nd:YAG Laser. *Dermatol Surg* 2006;32:241–248 discussion 247
- Prado A, Andrades P, Danilla S, Leniz P, Castillo P, Gaete F. A prospective, randomized, double-blind, controlled clinical trial comparing laser-assisted lipoplasty with suction-assisted lipoplasty. *Plast Reconstr Surg* 2006;118:1032–1045
- Liu H, Dang Y, Wang Z, Chai X, Ren Q. Laser induced collagen remodeling: a comparative study in vivo on mouse model. *Lasers Surg Med* 2008;40:13–19
- DiBernardo BE, Reyes J, Chen B. Evaluation of tissue thermal effects from 1064/1320-nm laser-assisted lipolysis and its clinical implications. *J Cosmet Laser Ther* 2009; 11:62–69
- Zhang Z, Li G, Shi B. Physicochemical properties of collagen, gelatin and gelatin hydrolysate derived from bovine limed split wastes. *J Soc Leather Technol Chemists* 2005; 90:23–28
- Kist DA, Sierra R, Sherr E, Zelickson BD. Collagen fibril contraction in bovine tendon and poultry skin after CO<sub>2</sub> laser exposure. *Lasernews Net* 2004;2:15–23
- Alam M, Hsu TS, Dover JS, Wrone DA, Arndt KA. Nonablative laser and light treatments: histology and tissue effects—a review. *Lasers Surg Med* 2003;33:30–39
- Chan HH, Lam LK, Wong DS, Kono T, Trendell-Smith N. Use of 1,320 nm Nd: YAG laser for wrinkle reduction and the treatment of atrophic acne scarring in Asians. *Lasers Surg Med* 2004;34:98–103
- Weiss RA, Weiss MA, Beasley KL, Munavalli G. Our approach to non-ablative treatment of photoaging. *Lasers Surg Med* 2005;37:2–8
- DiBernardo BE, Reyes J. Evaluation of skin tightening after laser-assisted liposuction. *Aesthet Surg J* 2009;29:400–407
- Sasaki GH, Tevez A. Laser-assisted liposuction for facial and body contouring and tissue tightening: a 2-year experience with 75 consecutive patients. *Semin Cutan Med Surg* 2009; 28:226–235
- Sun Y, Wu SF, Yan S, Shi HY, Chen D, Chen Y. Laser lipolysis used to treat localized adiposis: a preliminary report on experience with Asian patients. *Aesthetic Plast Surg* 2009; 33:701–705
- Mordon S, Eymard-Maurin AF, Wassmer B, Ringot J. Histologic evaluation of laser lipolysis: pulsed 1064-nm Nd:YAG laser versus cw 980-nm diode laser. *Aesthet Surg J* 2007;27:263–268